



**8th Advanced Course
on Knee Surgery**



How to make your decision in primary TKA

How I do my perfect medial approach

Francesco Benazzo

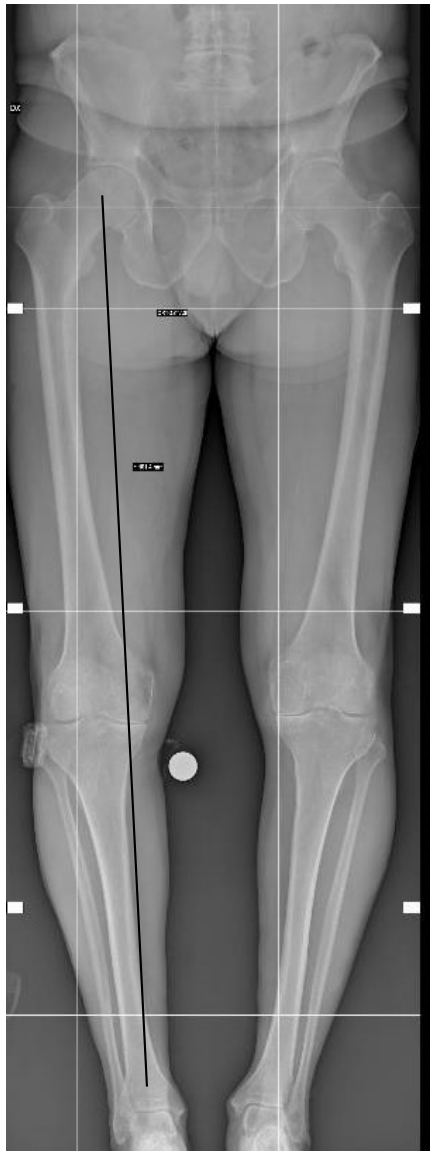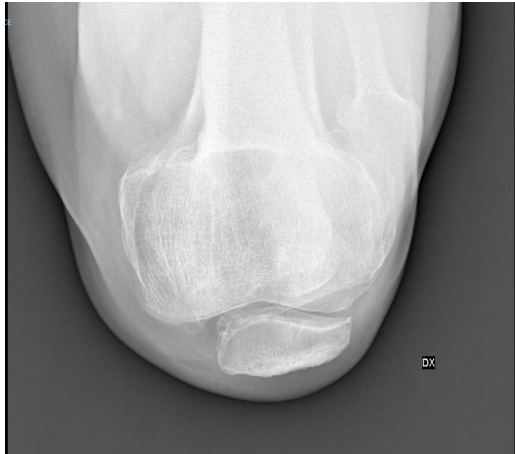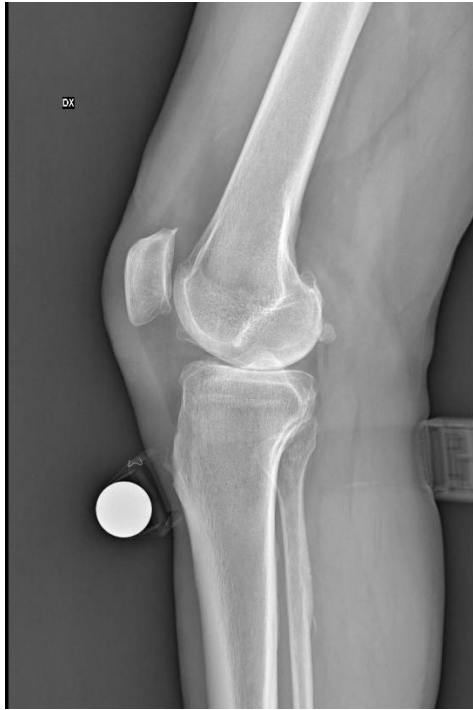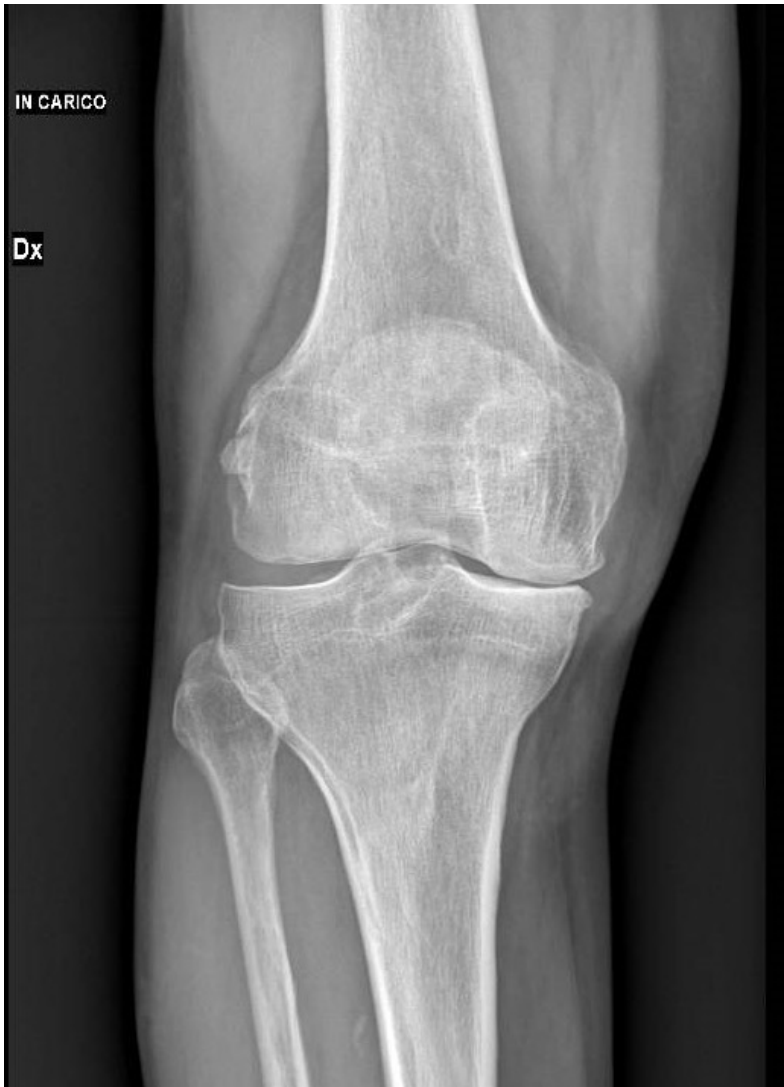MEDIAL APPROACH

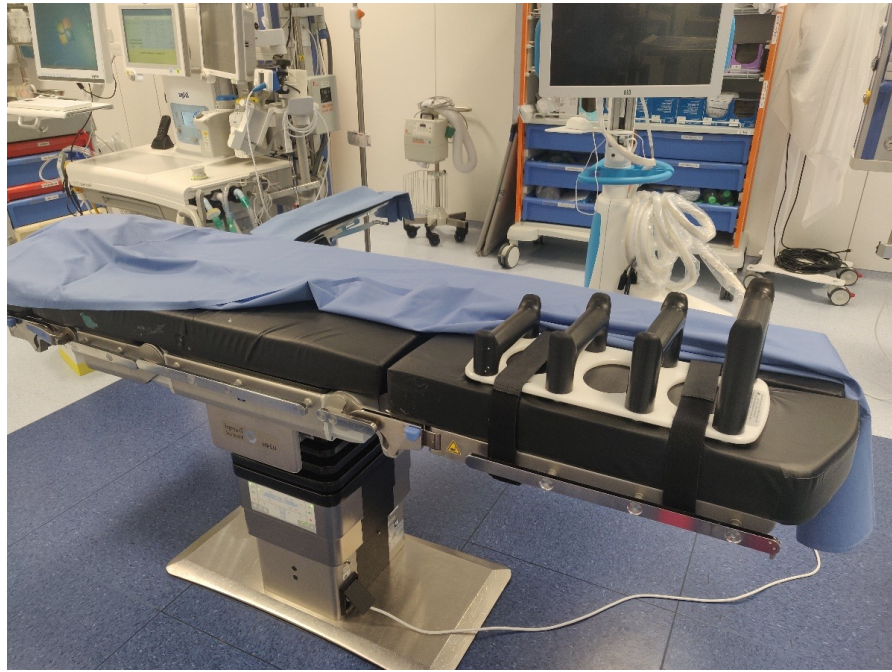- UKA
- TKA simple
- TKA difficult

MEDIAL APPROACH

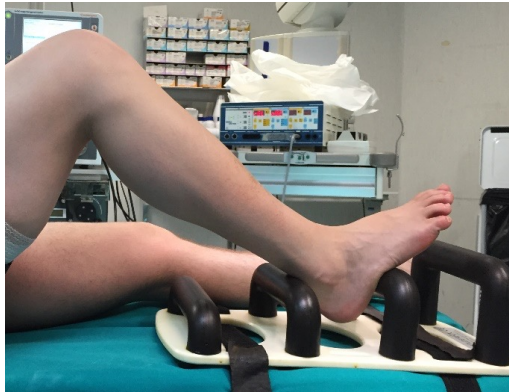UKA

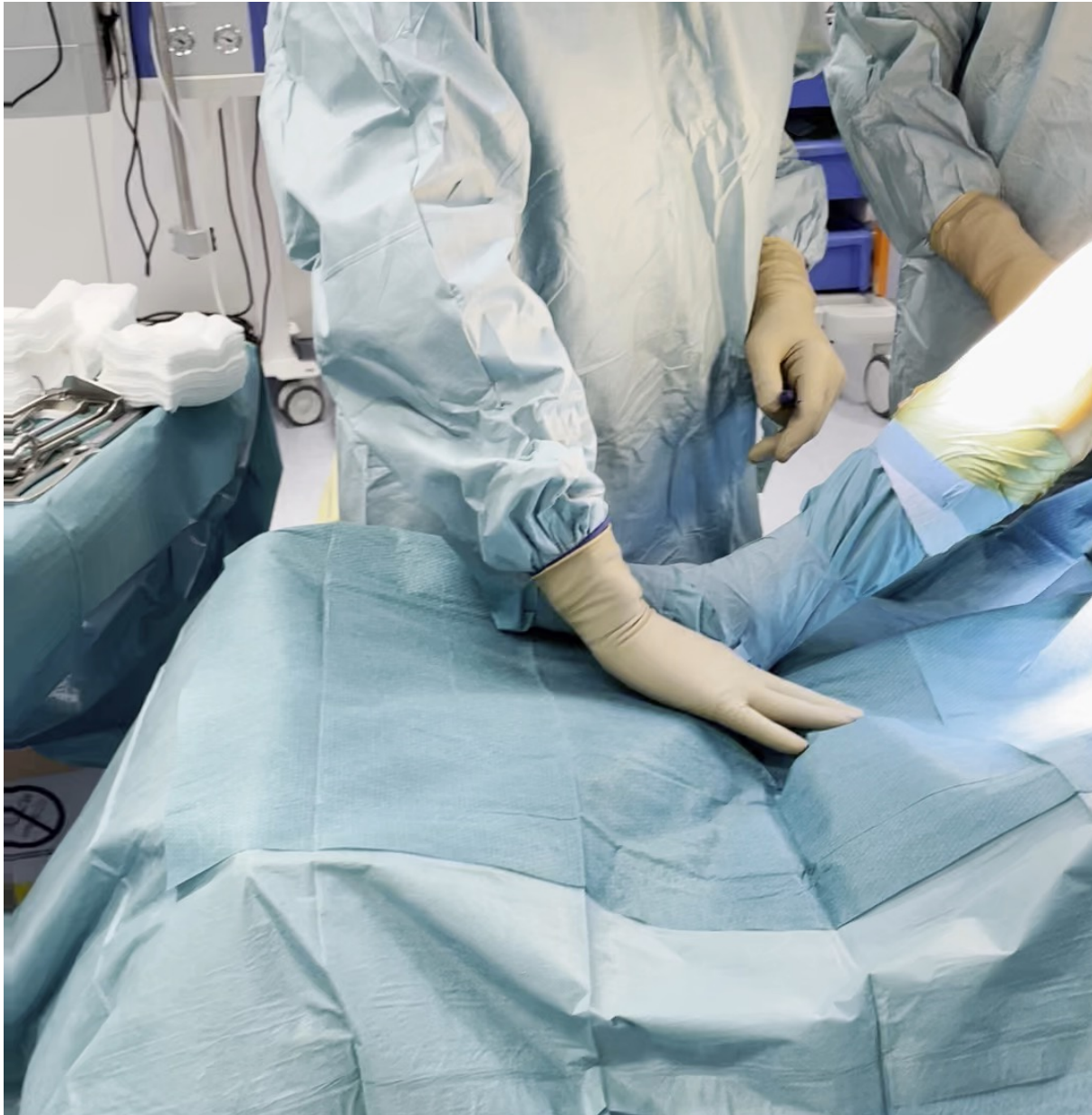
Z.M.,
M
67y





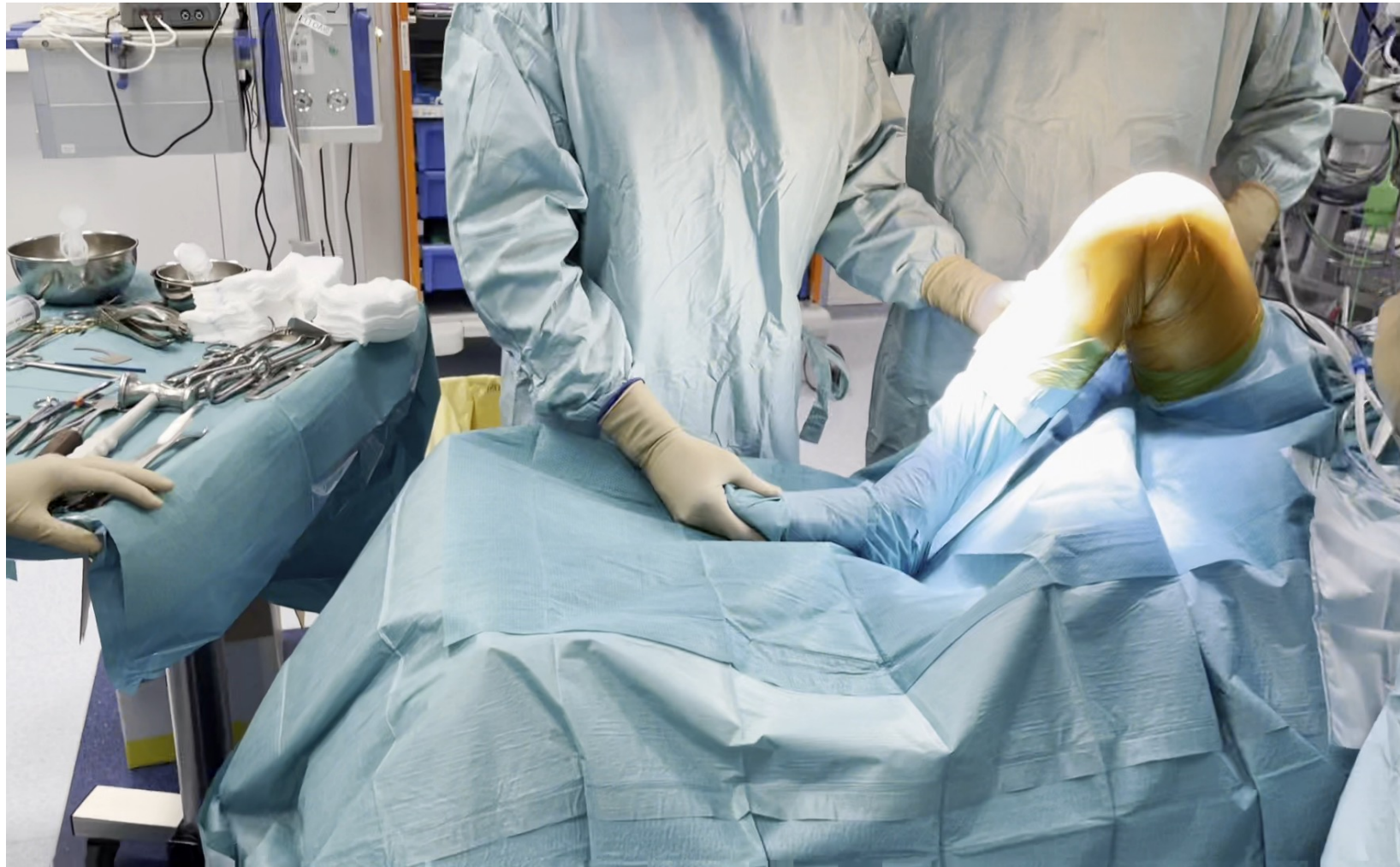
Preparation





Set-up

- Leg-holder
- Set the needed flexion(s)

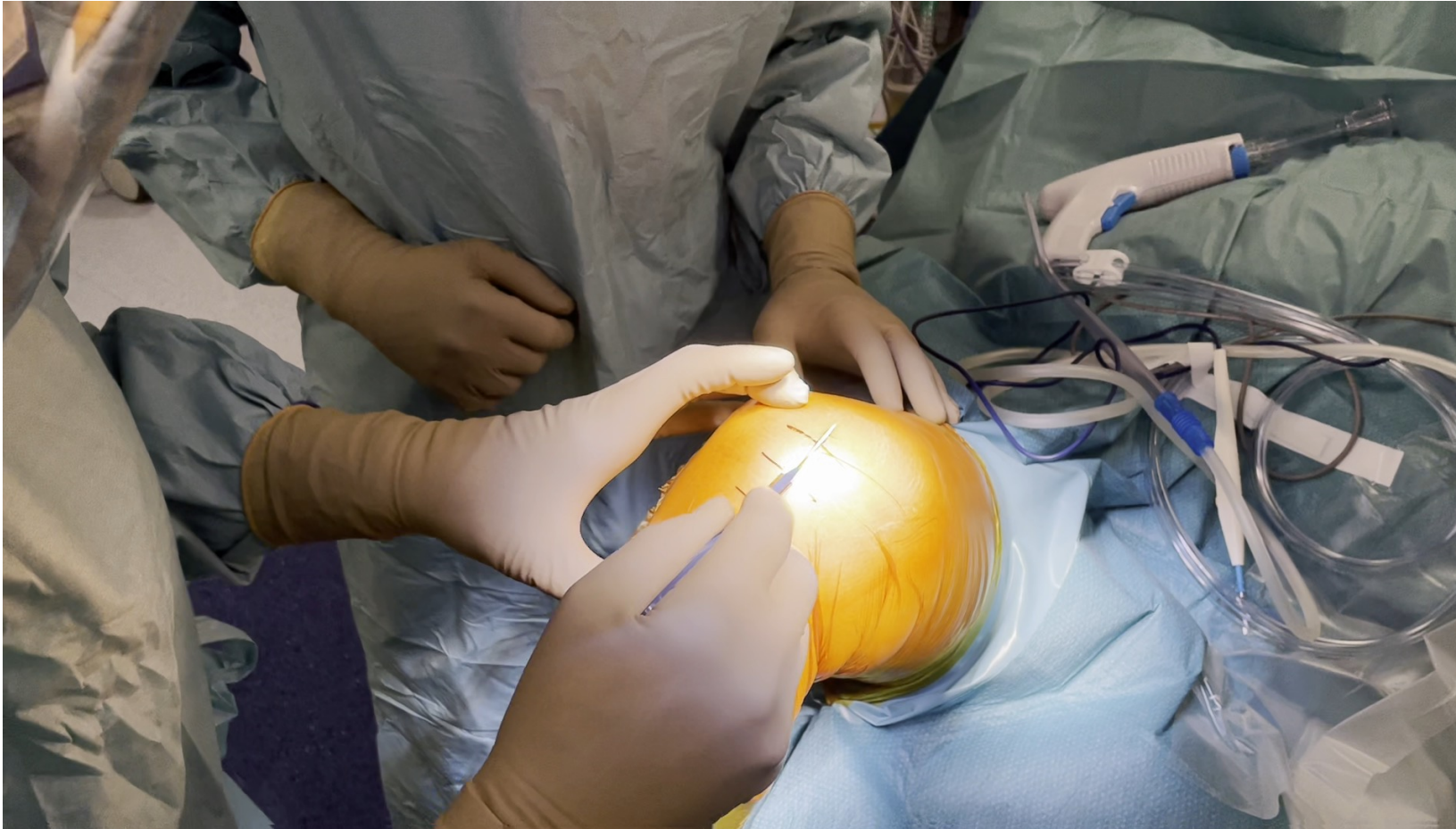

Choice of incision

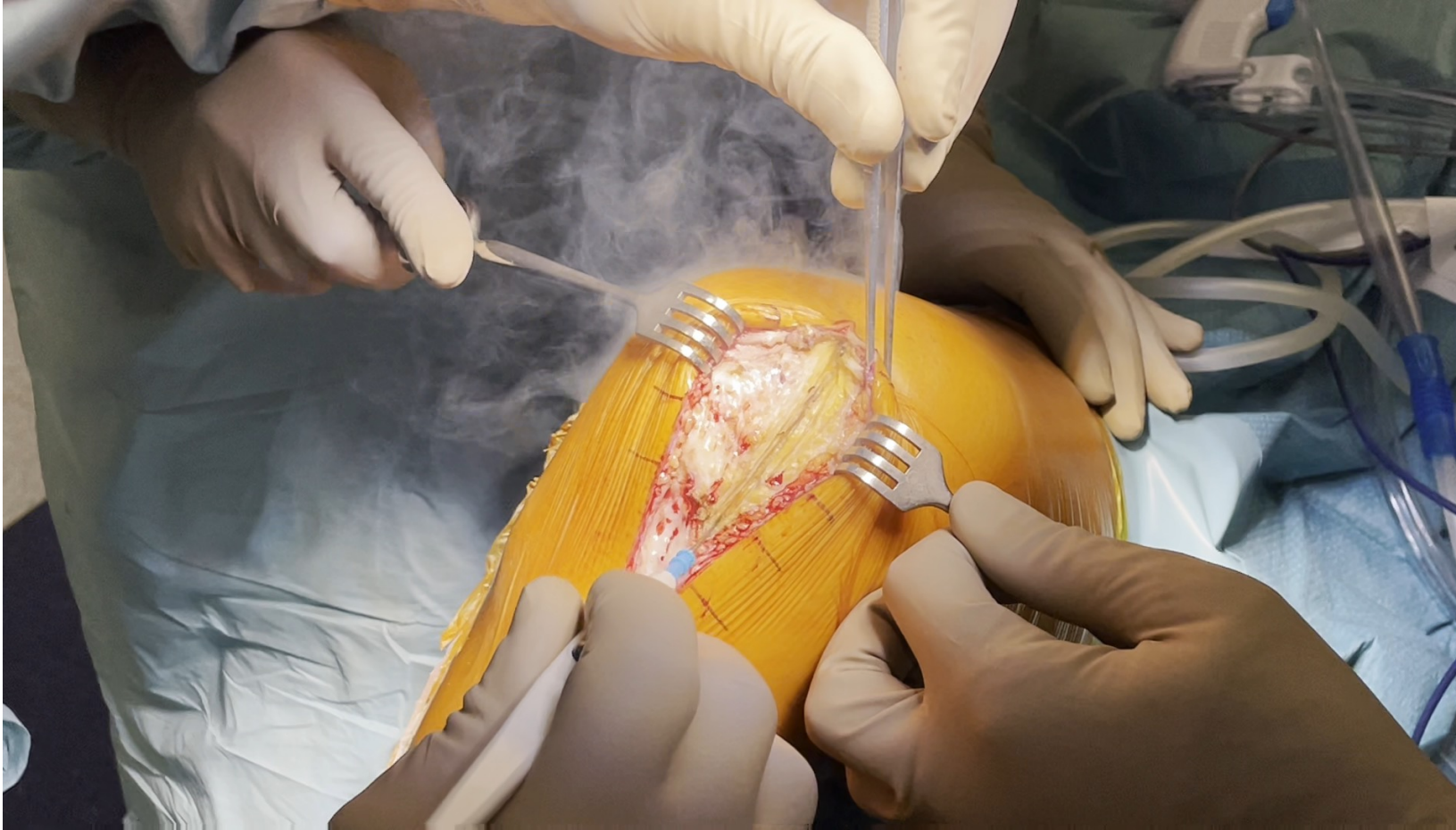- Draw your incision
- medial incision

Easy knee (UNI)

- Slightly medial incision
- Parapatellar capsular incision, ending at the proximal pole of the patella
- Lateral displacement of the patella
- Removal of the osteophytes

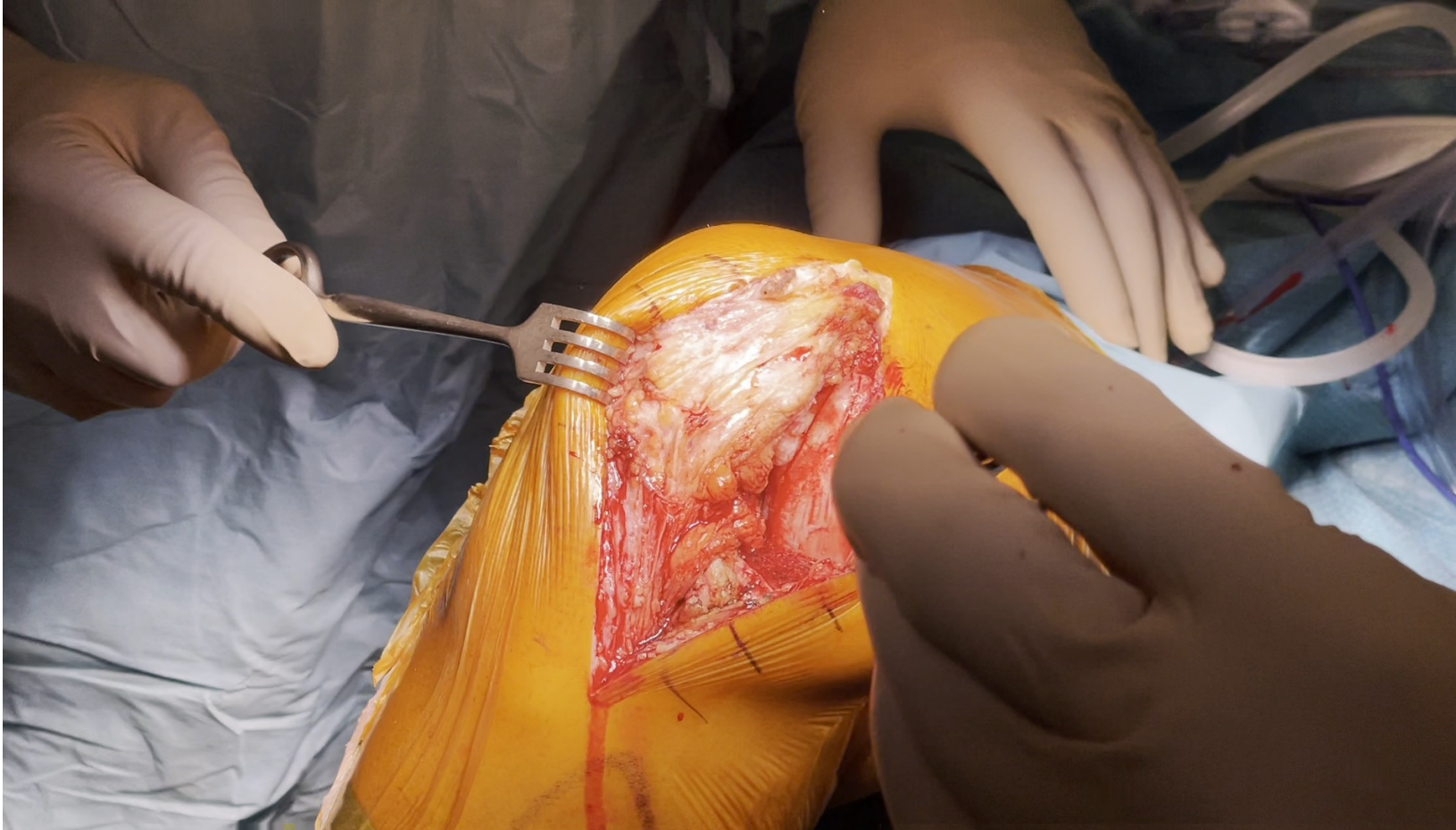


Approach



Approach:

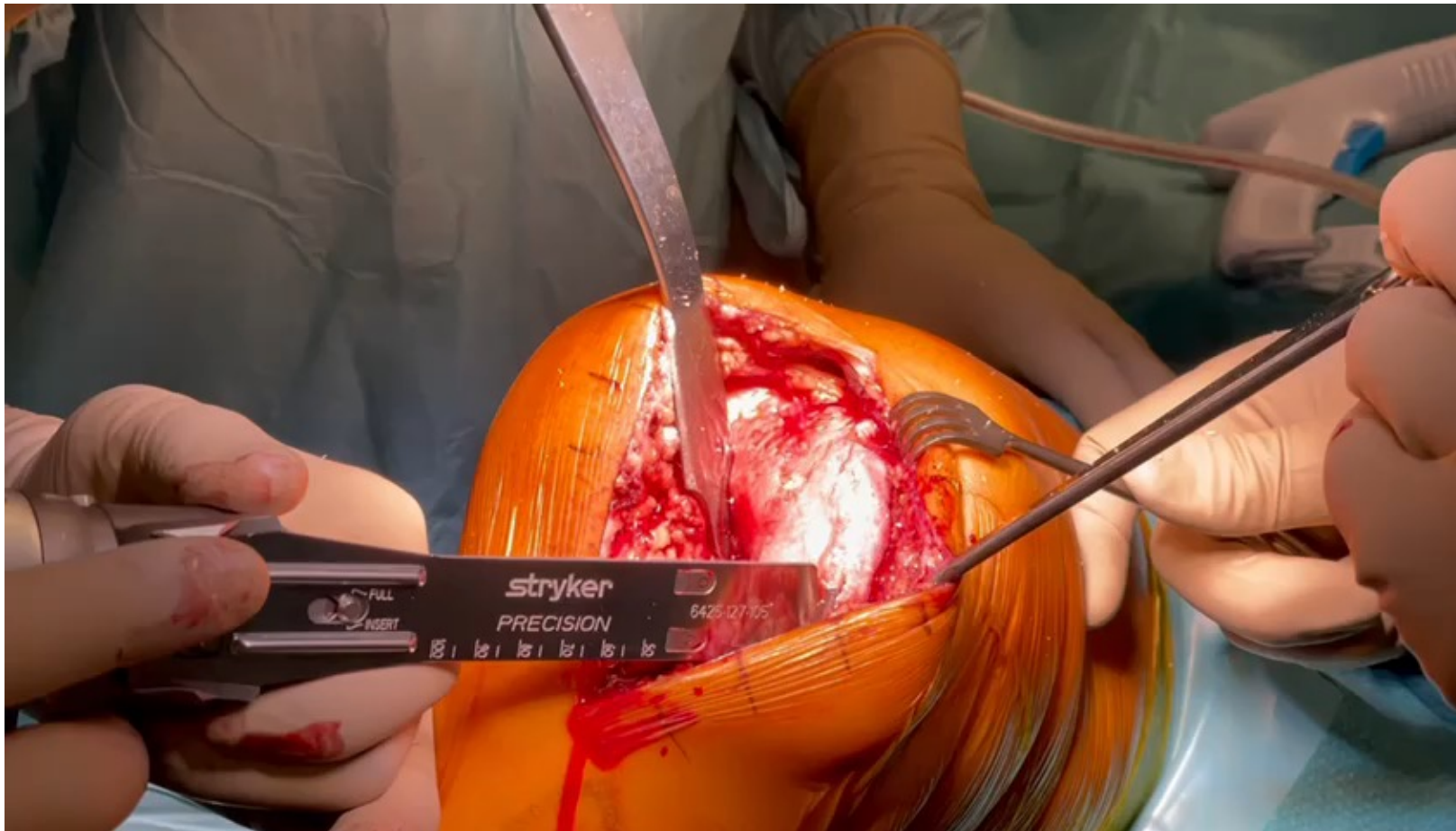
- Medial arthrotomy
- Cautery of Hoffa's Body



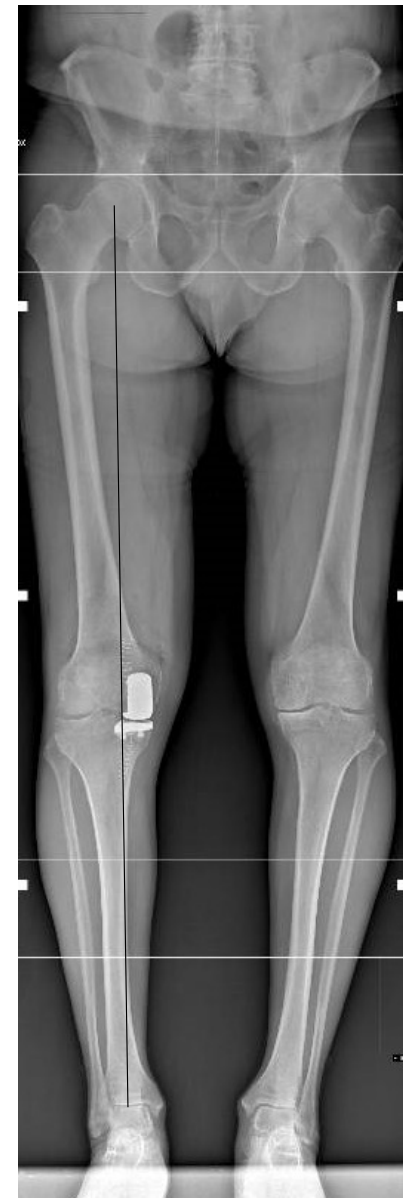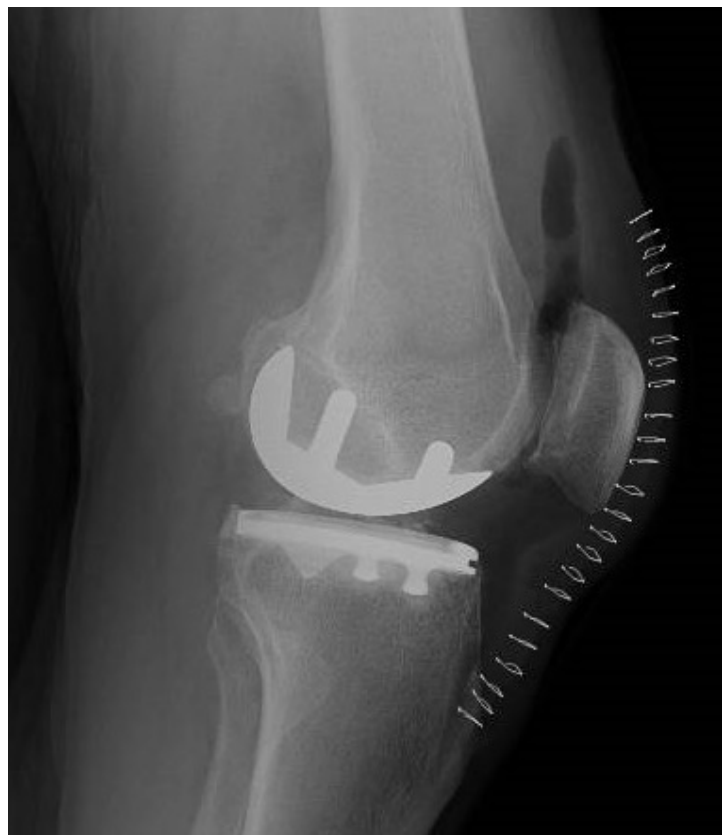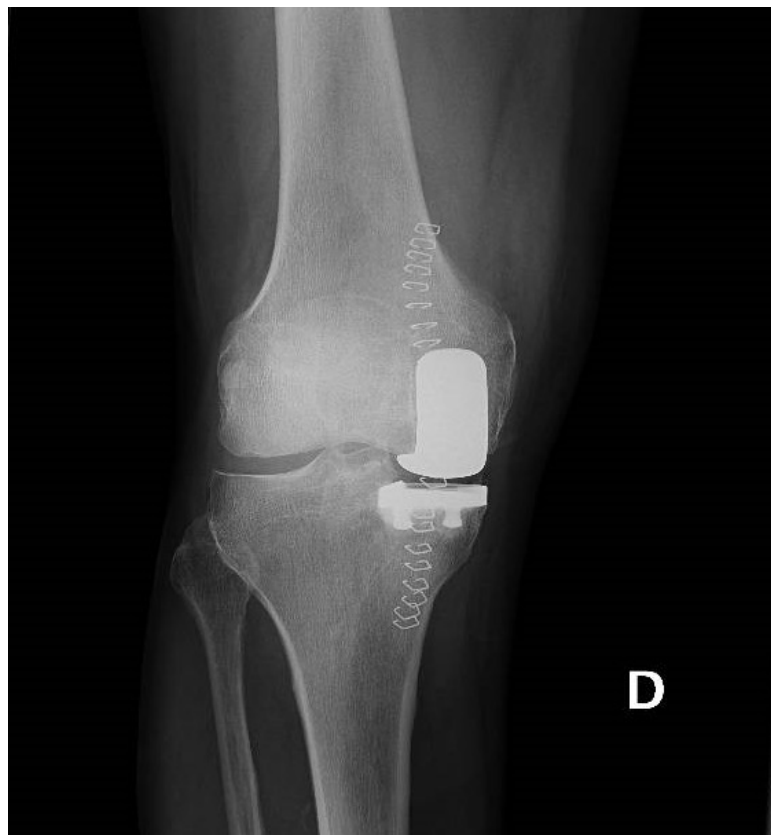Approach

- Partial removal of Hoffa's body
- Minimal/no detachment of medial capsule from tibia
- Lateralization of the patella on the lateral condyle

Removal of the osteophyte from the medial condyle



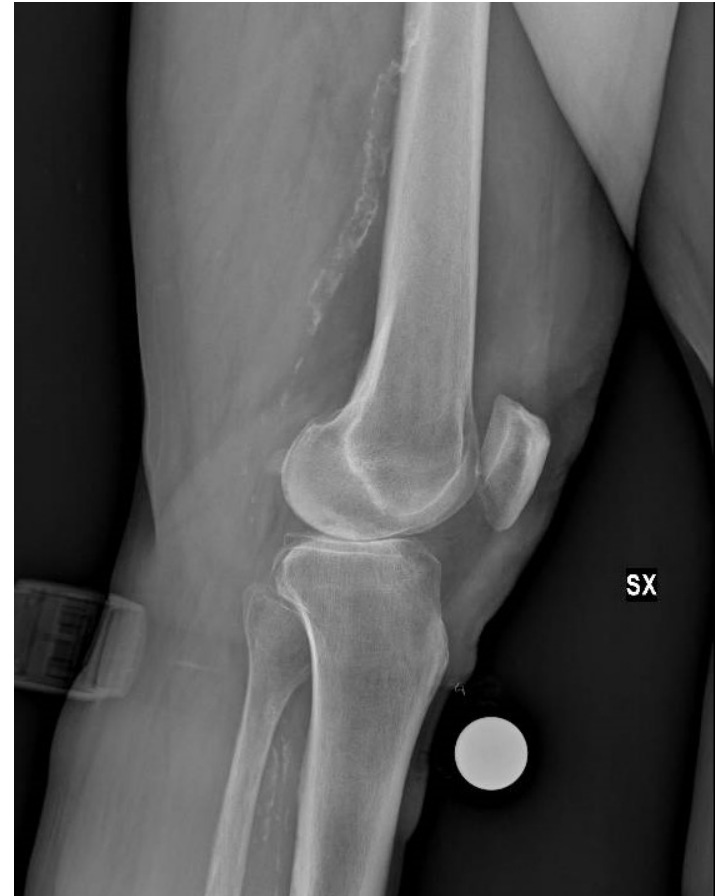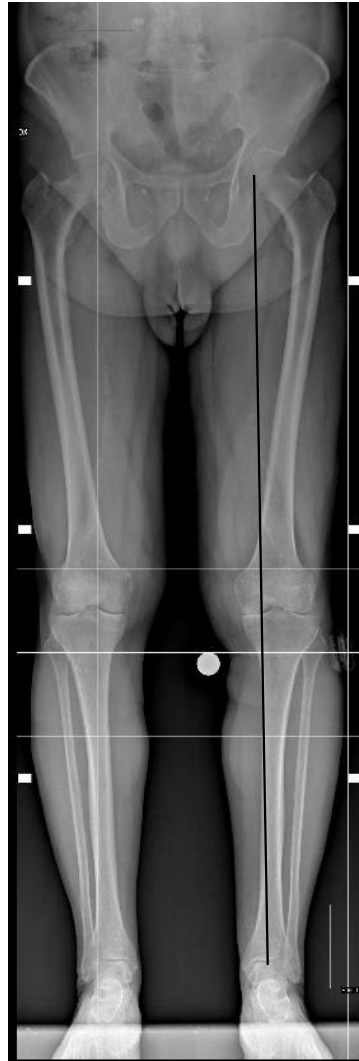Z.M.,
M
67yo



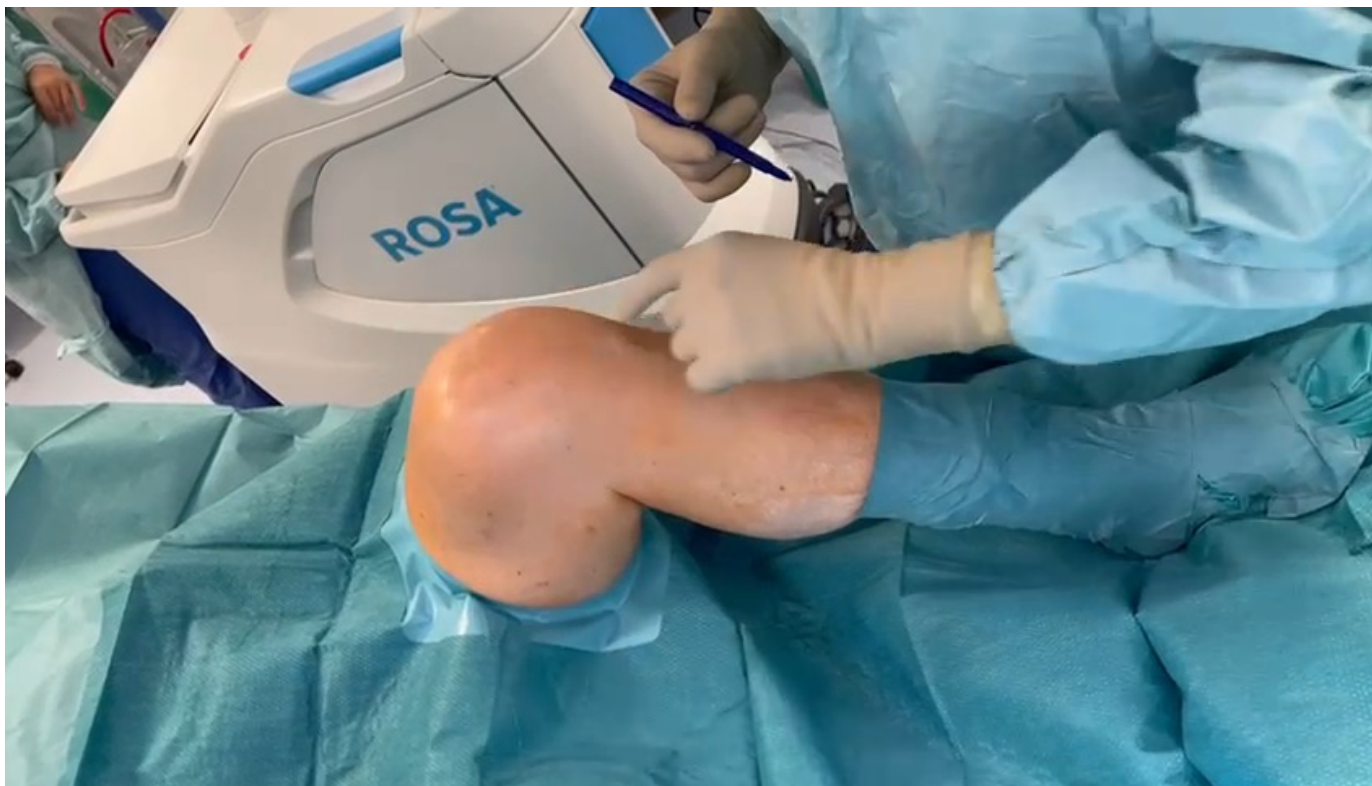MEDIAL APPROACH

TKA

R.T.F.,
M
67 y



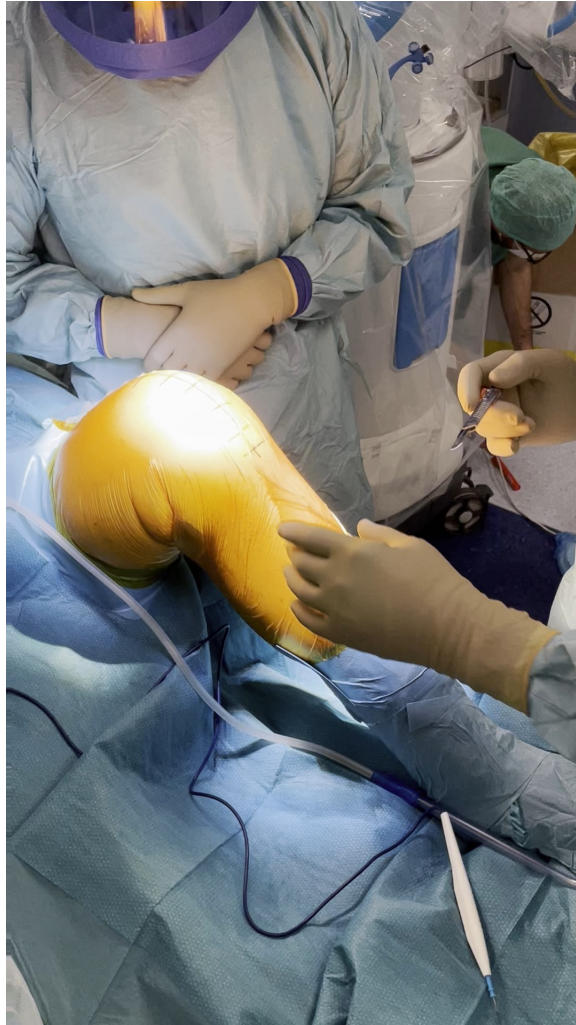Choice of incision



«Normal» knee (TKA)

- Median incision, from above the patella down to TT
- Parapatellar capsular incision, extended to the quad tendon after clear visualization of the Vastus
- Patella displaced fully laterally, (but not everted) after removal of the Hoffa's body
- Removal of the osteophytes
- ...

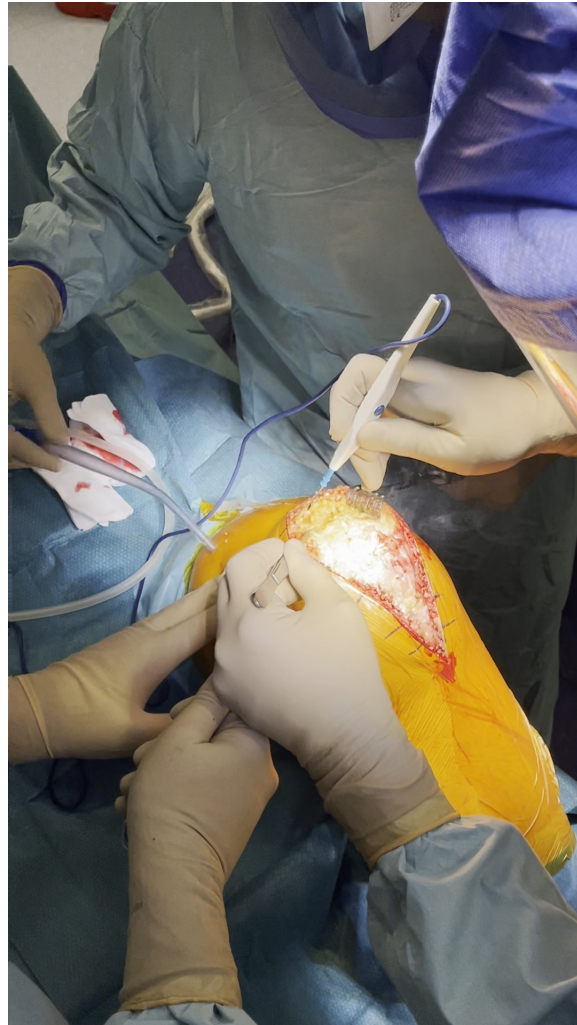
Approach



Approach

- Median Skin incision

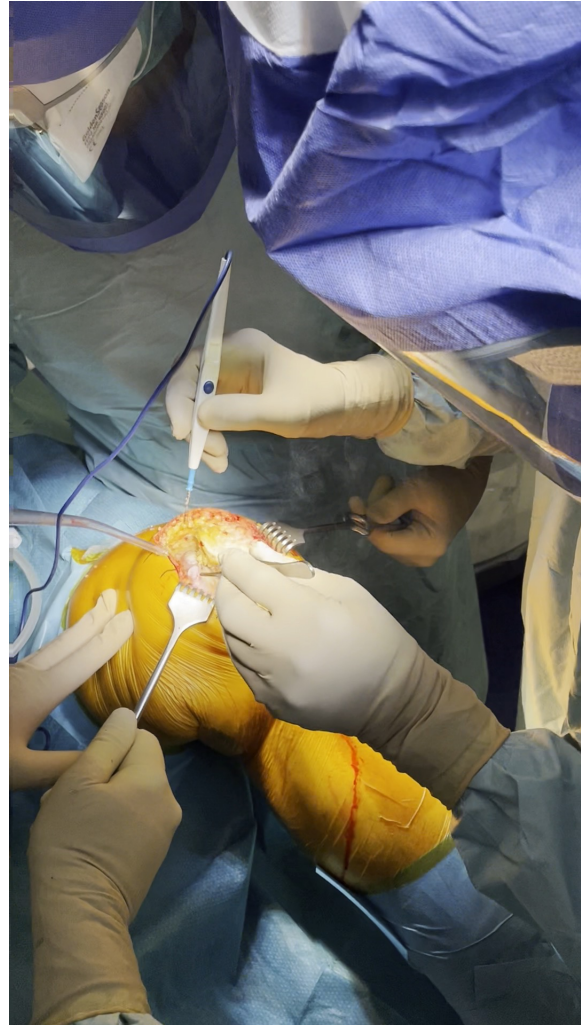Approach



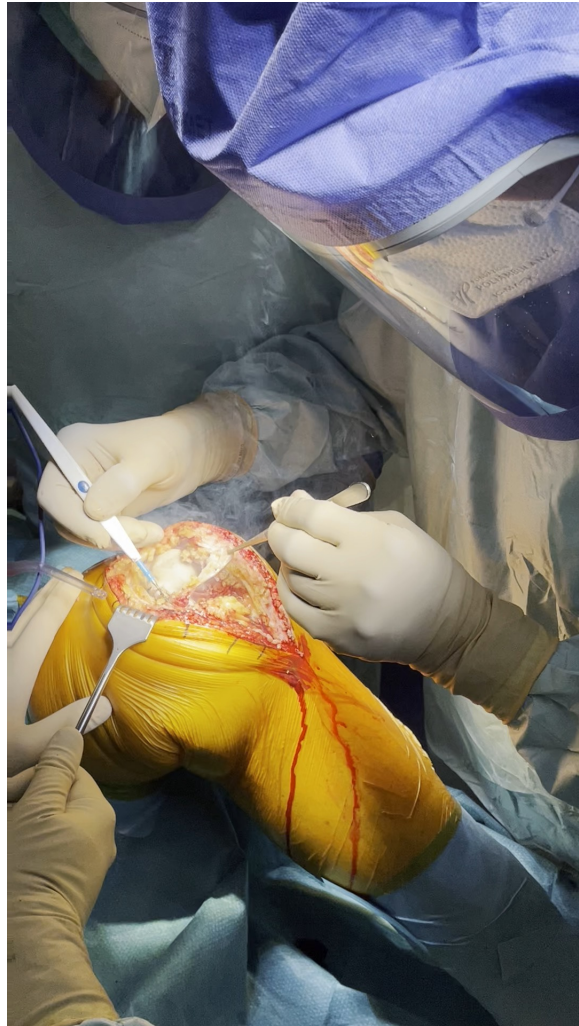Approach

Medial arthrotomy

Approach



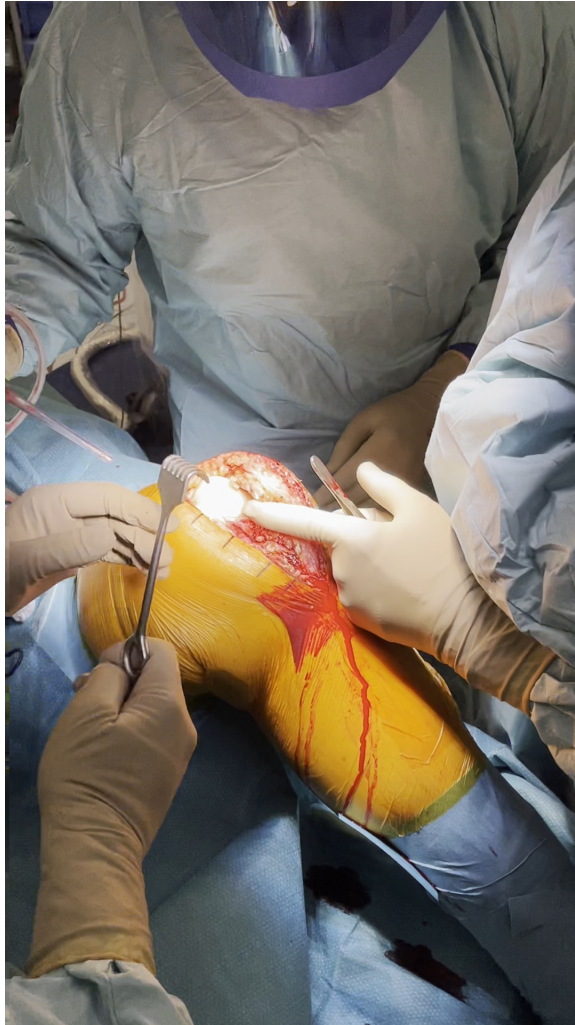Approach



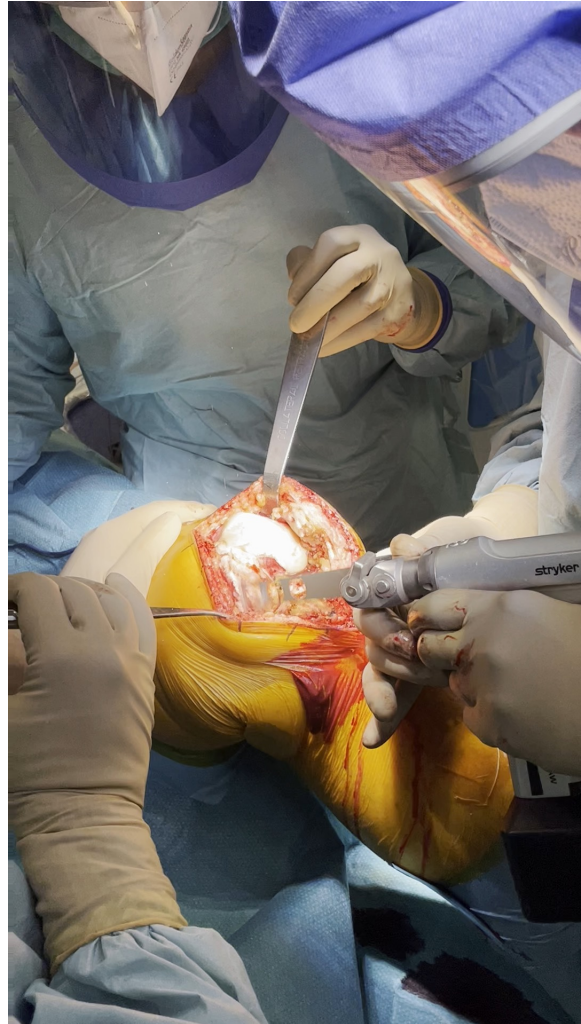Approach

- Removal of Hoffa's body
- Detachment of medial capsule from tibia
- Lateral displacement of the patella

Approach



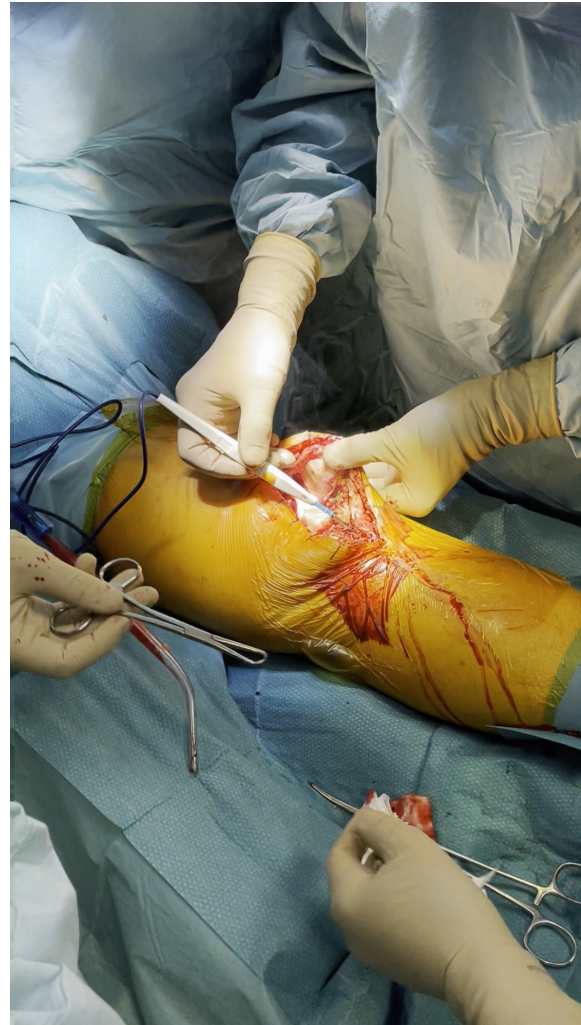Approach



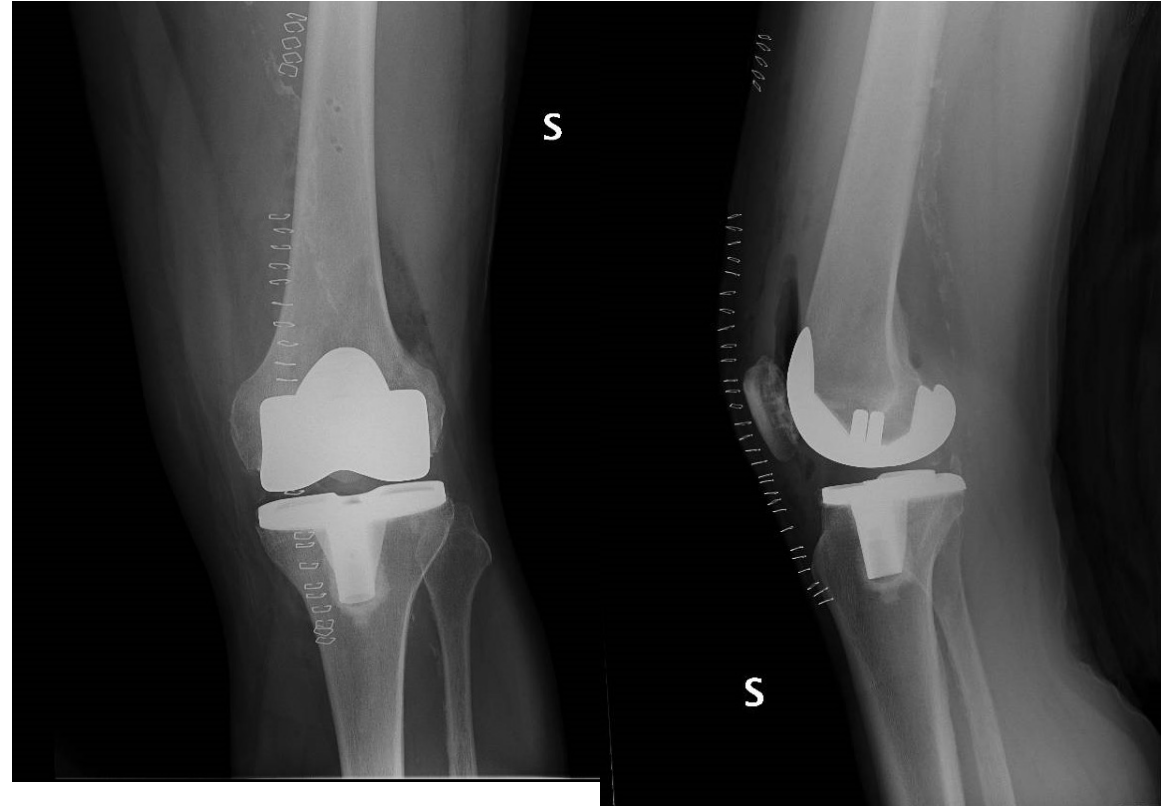
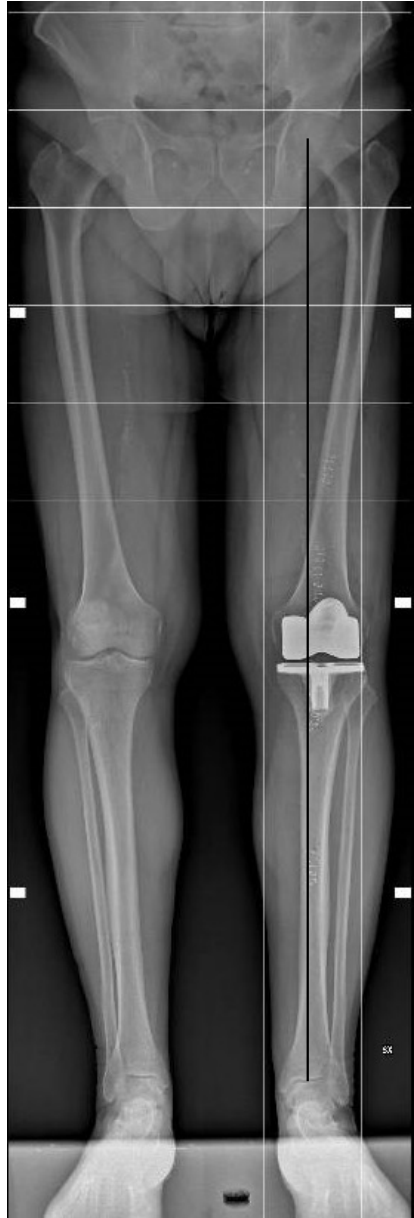Approach

- Osteophytes removal
- Minimal detachment of the patellar tendon
- Subtotal removal of the Hoffa's Body

Approach



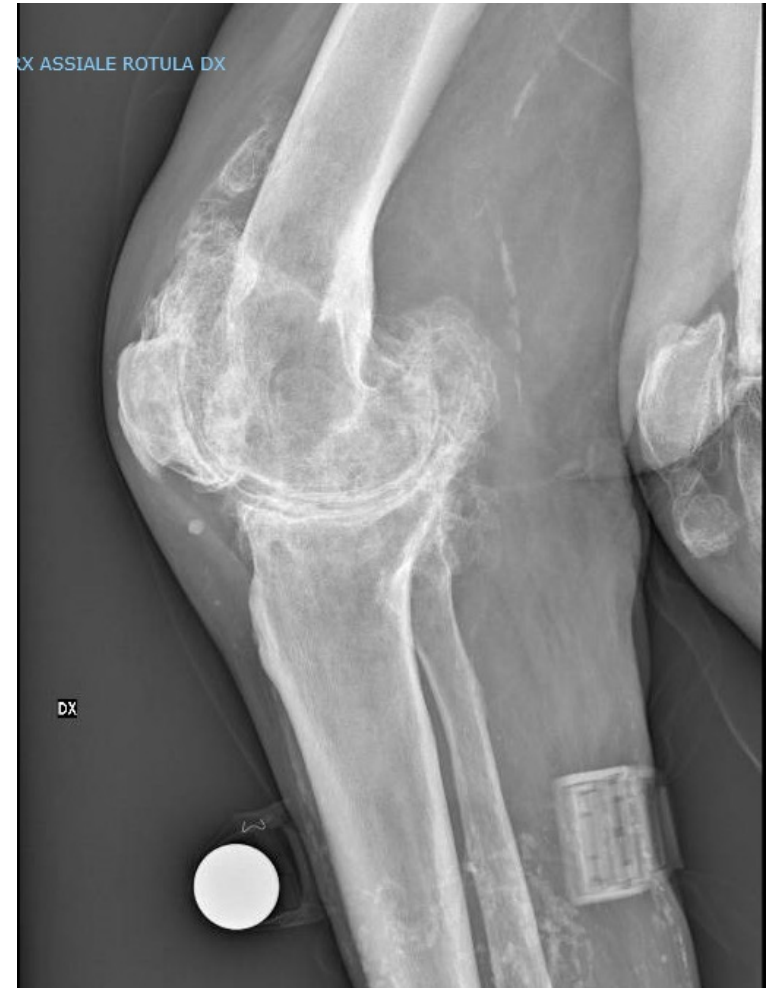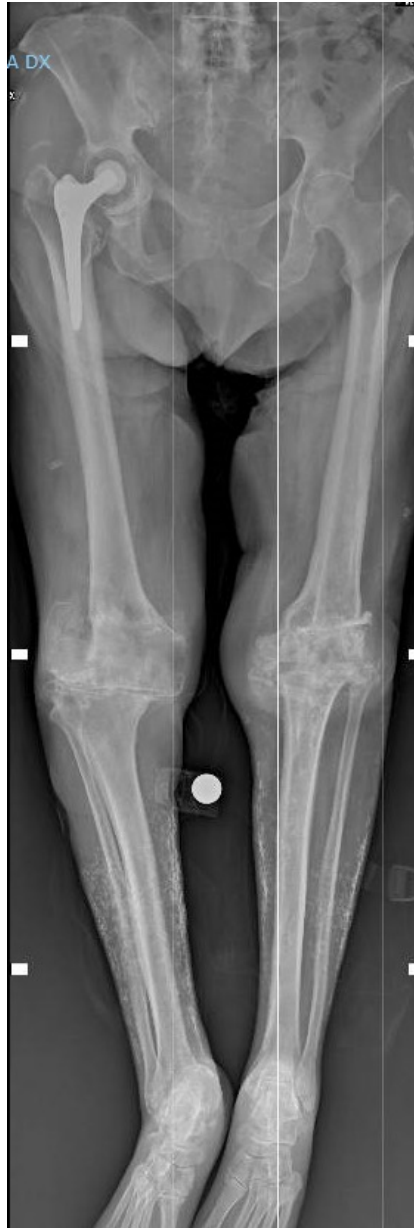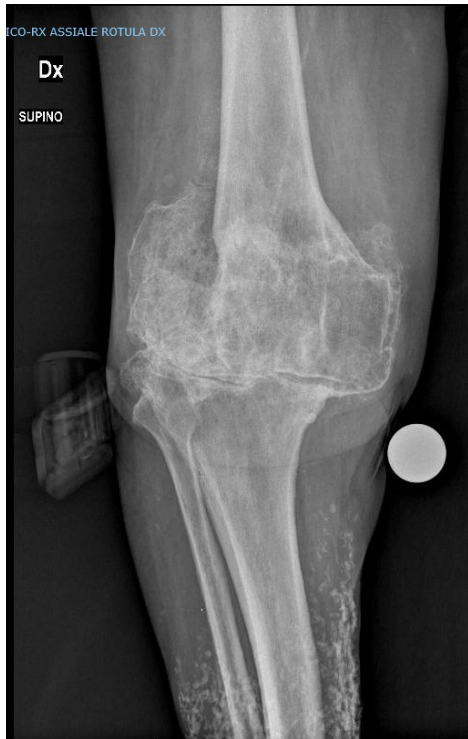R.T.F.,
M
67yo



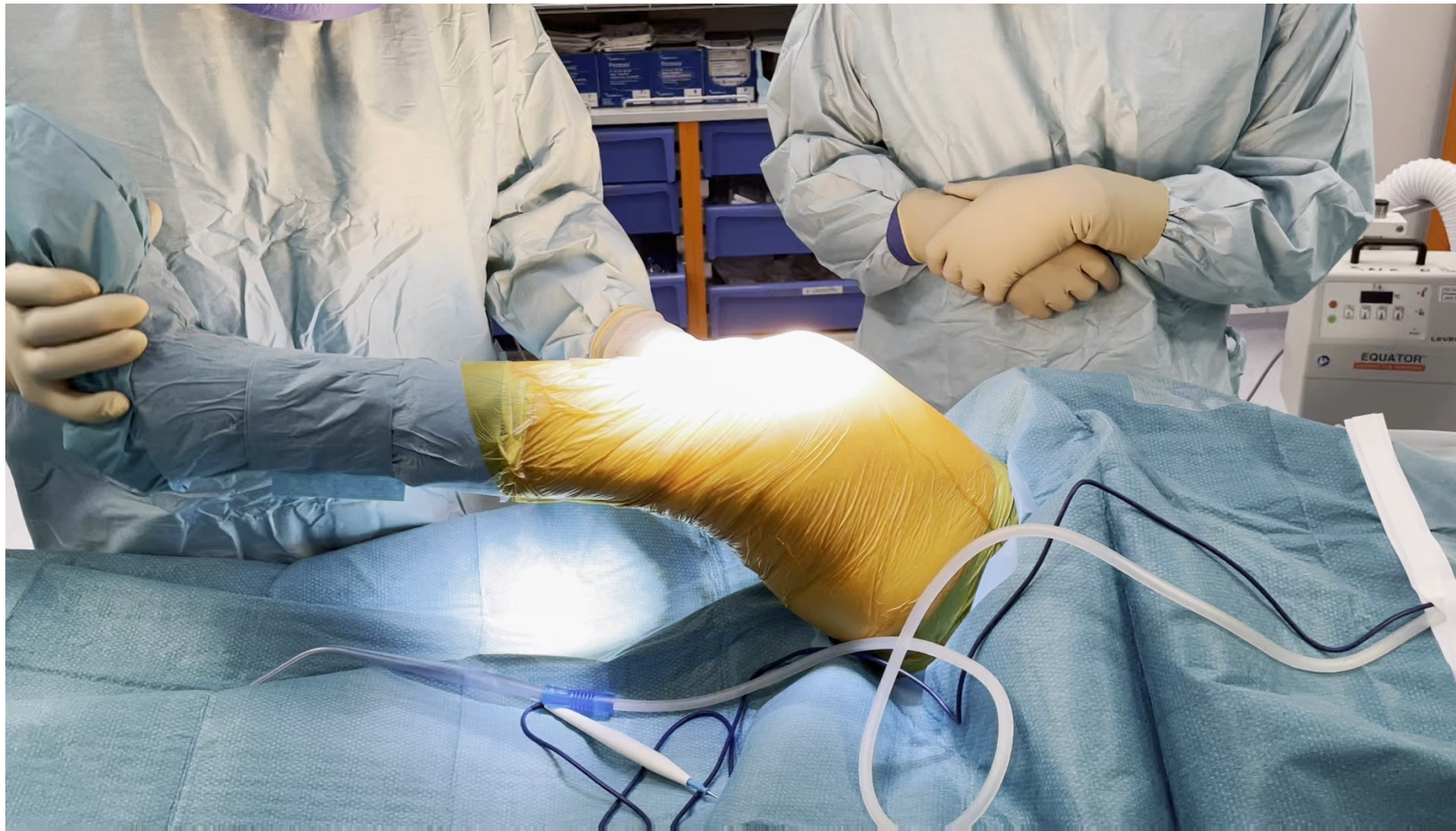
MEDIAL APPROACH

Difficult case

B.P.,
F
76 yo



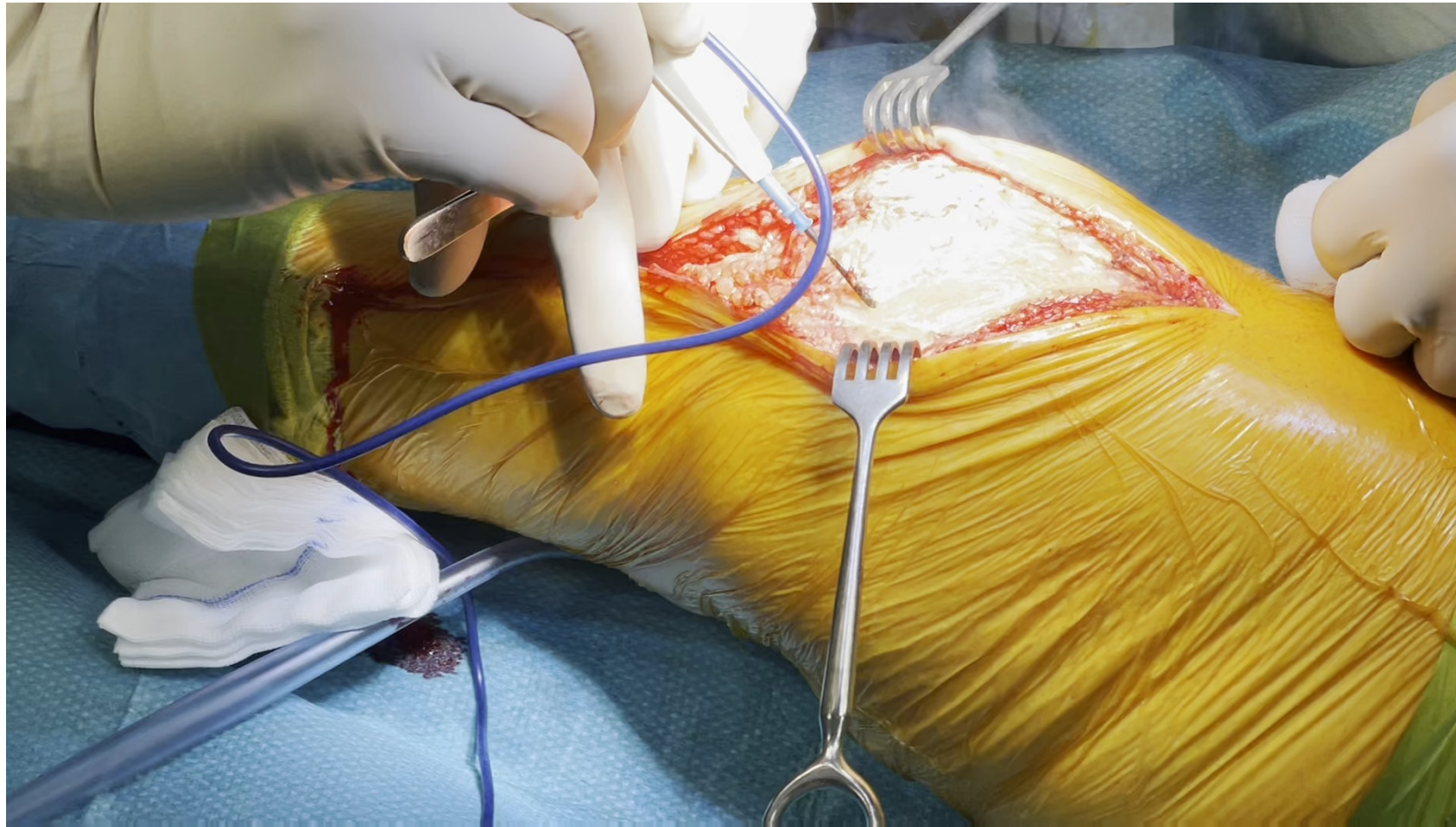
Pre-op evaluation



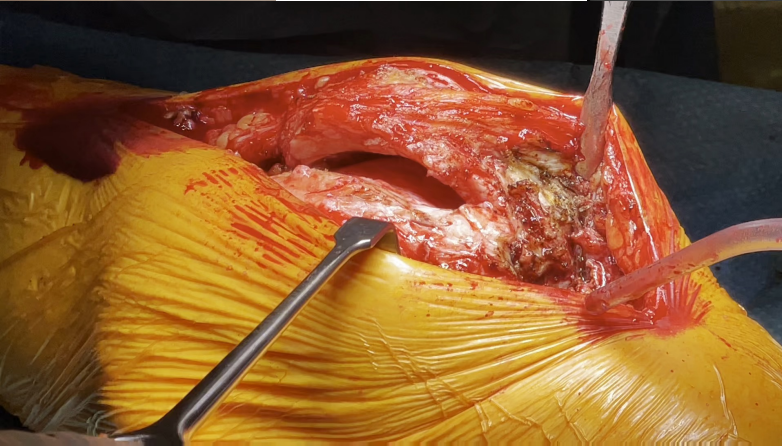
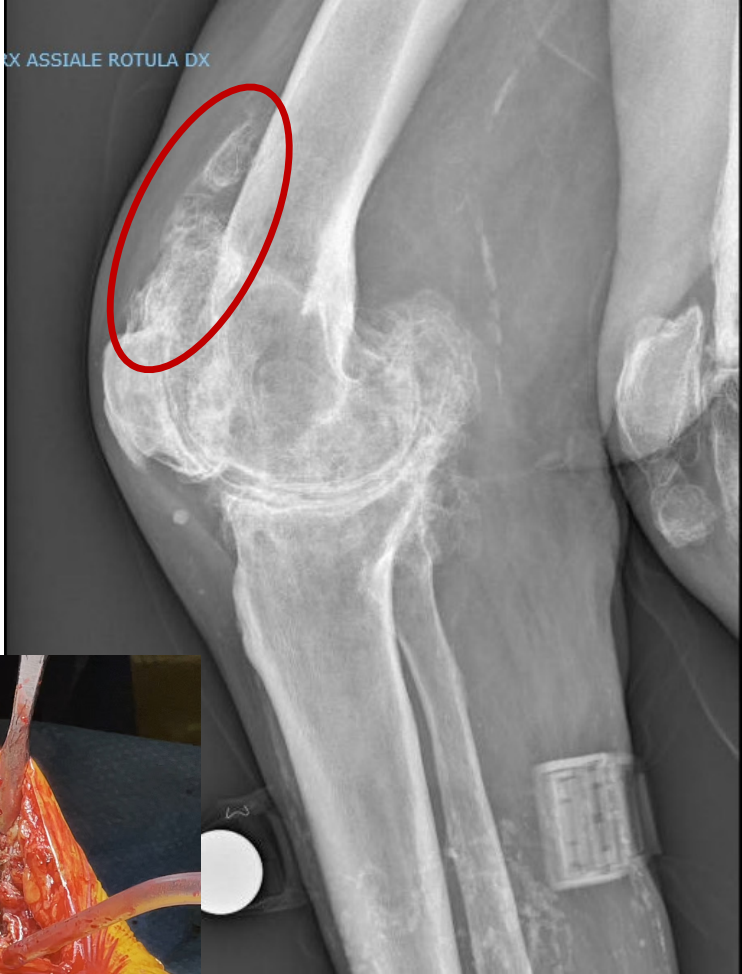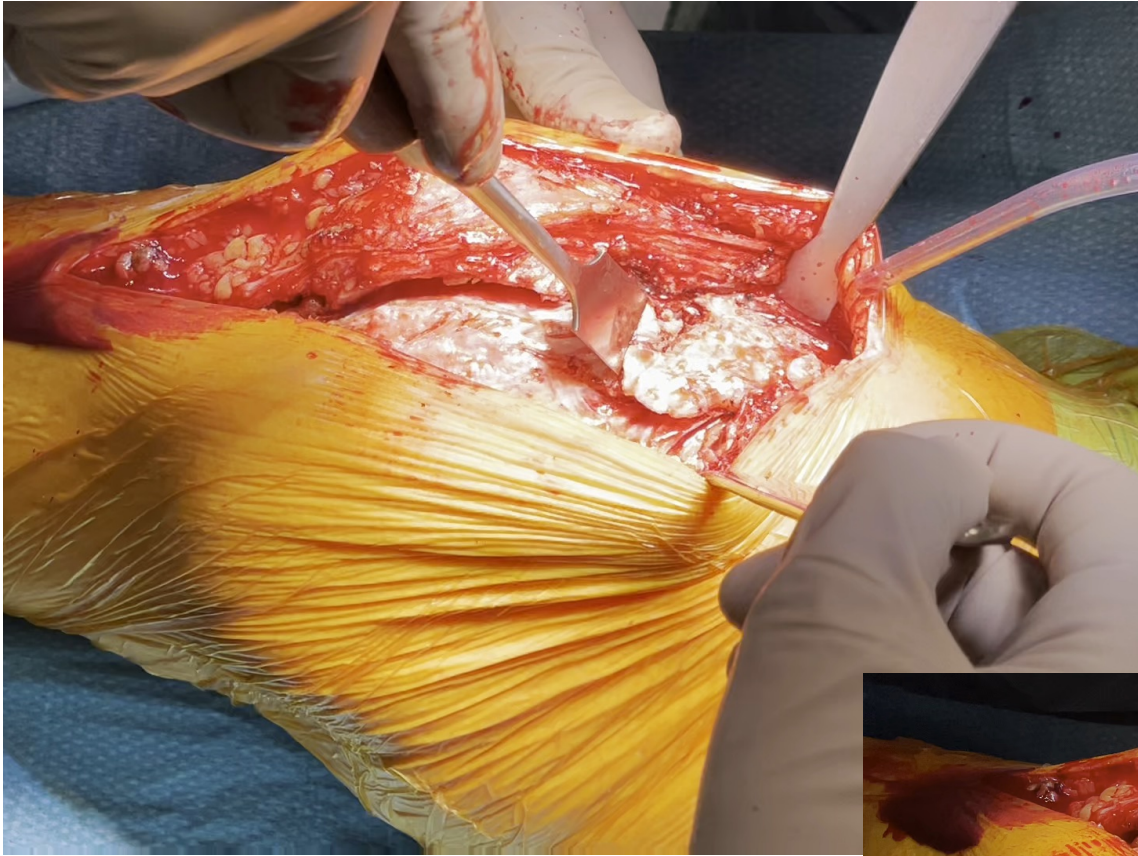«Difficult» knee (TKA)

- Step by step decision
- Progressively getting rid of the osteophytes → cuts of the gigantic osteophytes
- TT osteotomy (according to the hardware to be implanted)
- Reshaping the bones
- ...

Approach



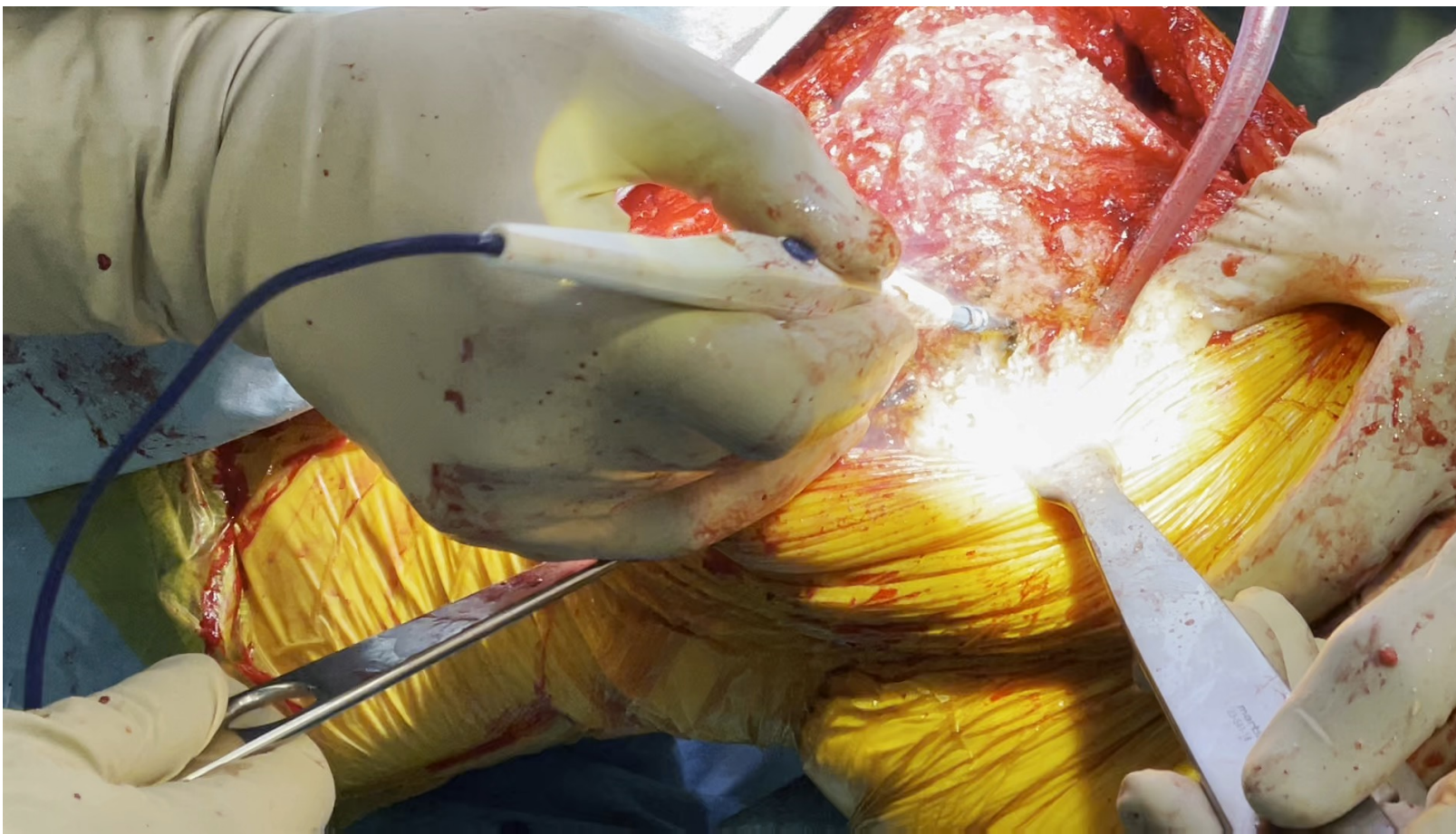
Removal of patellar calcification



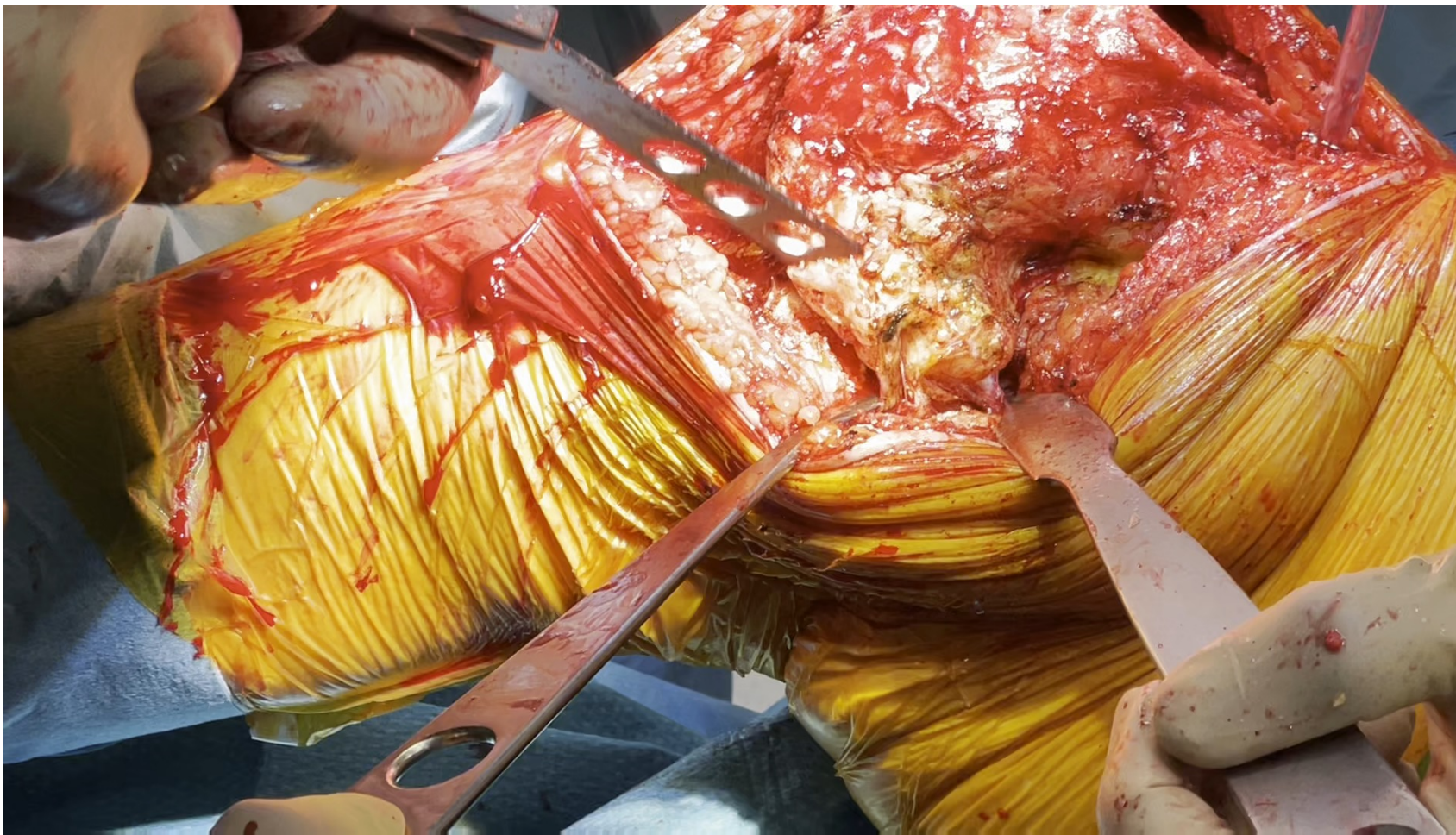Femoral remodeling



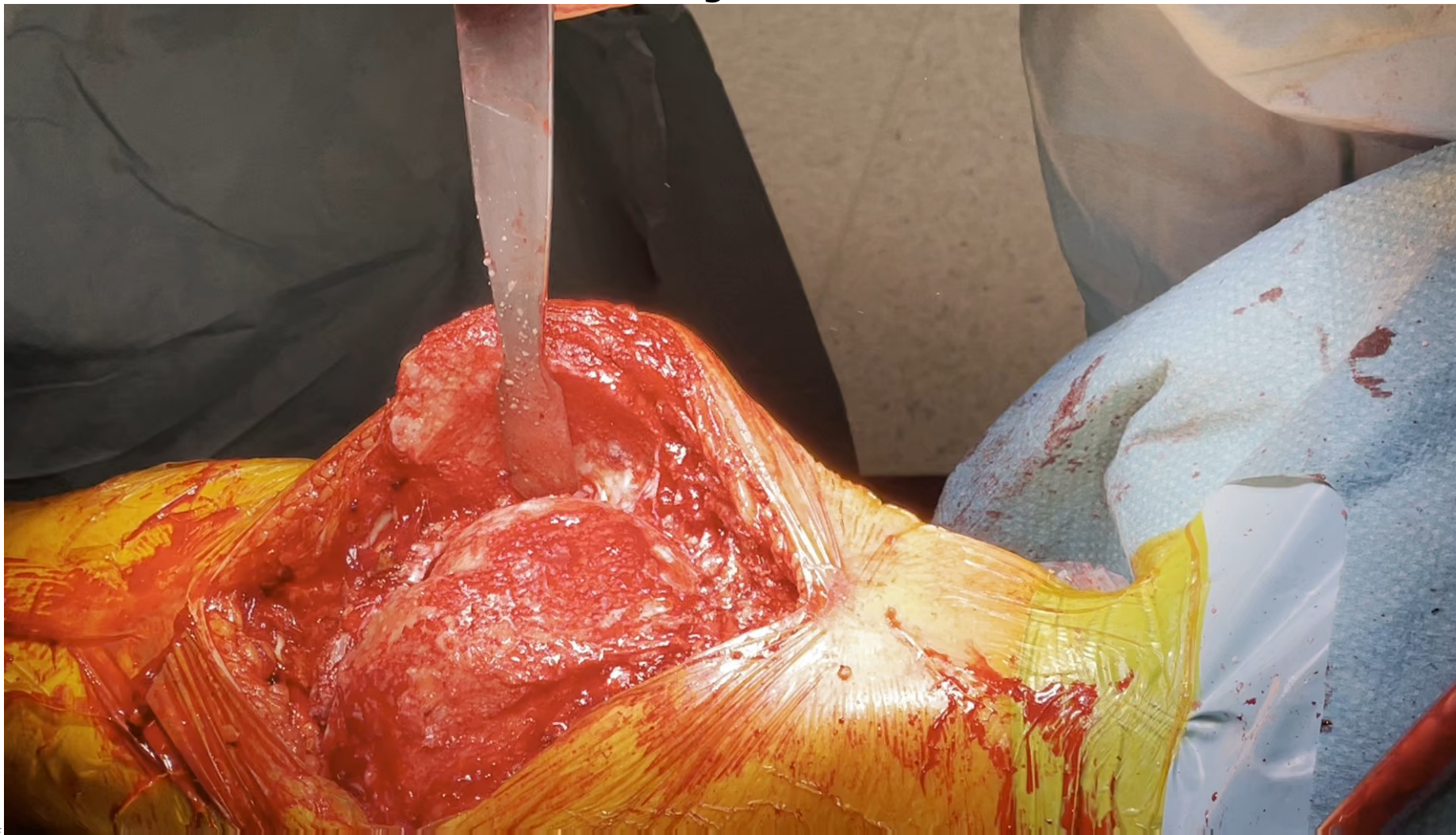
Femoral remodeling: posteromedial side



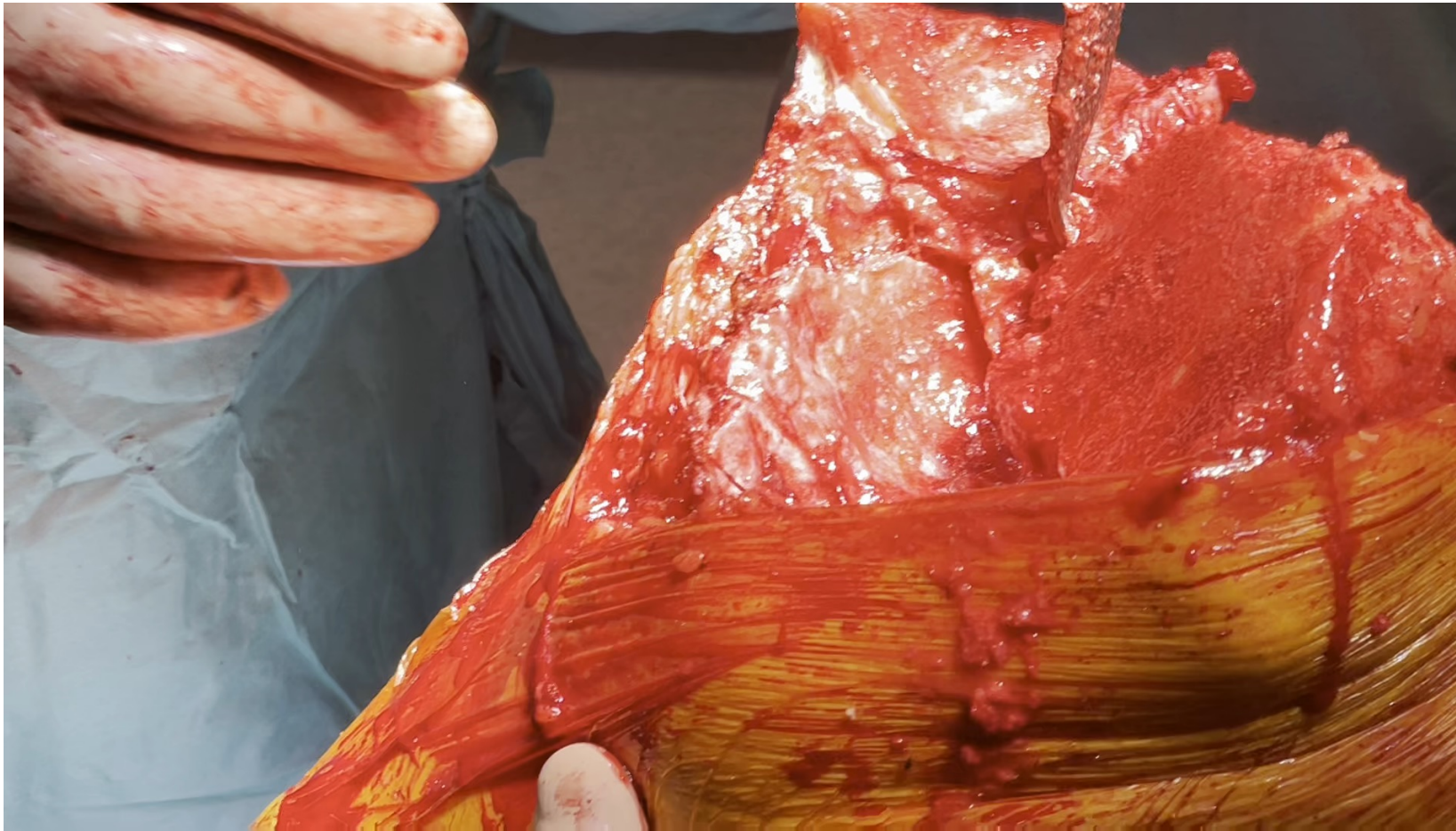Femoral remodeling: posteromedial side



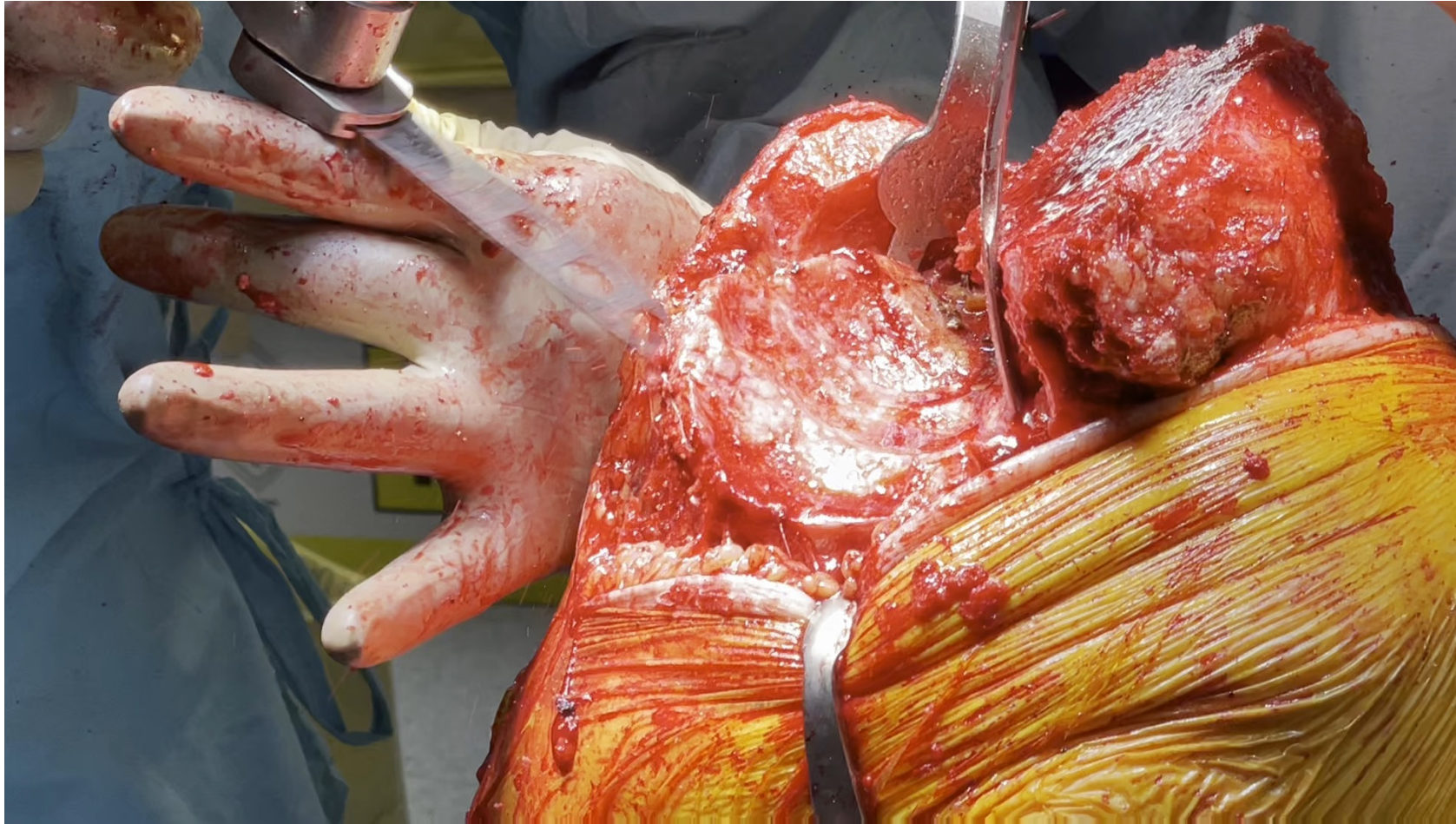Femoral remodeling: distal cut

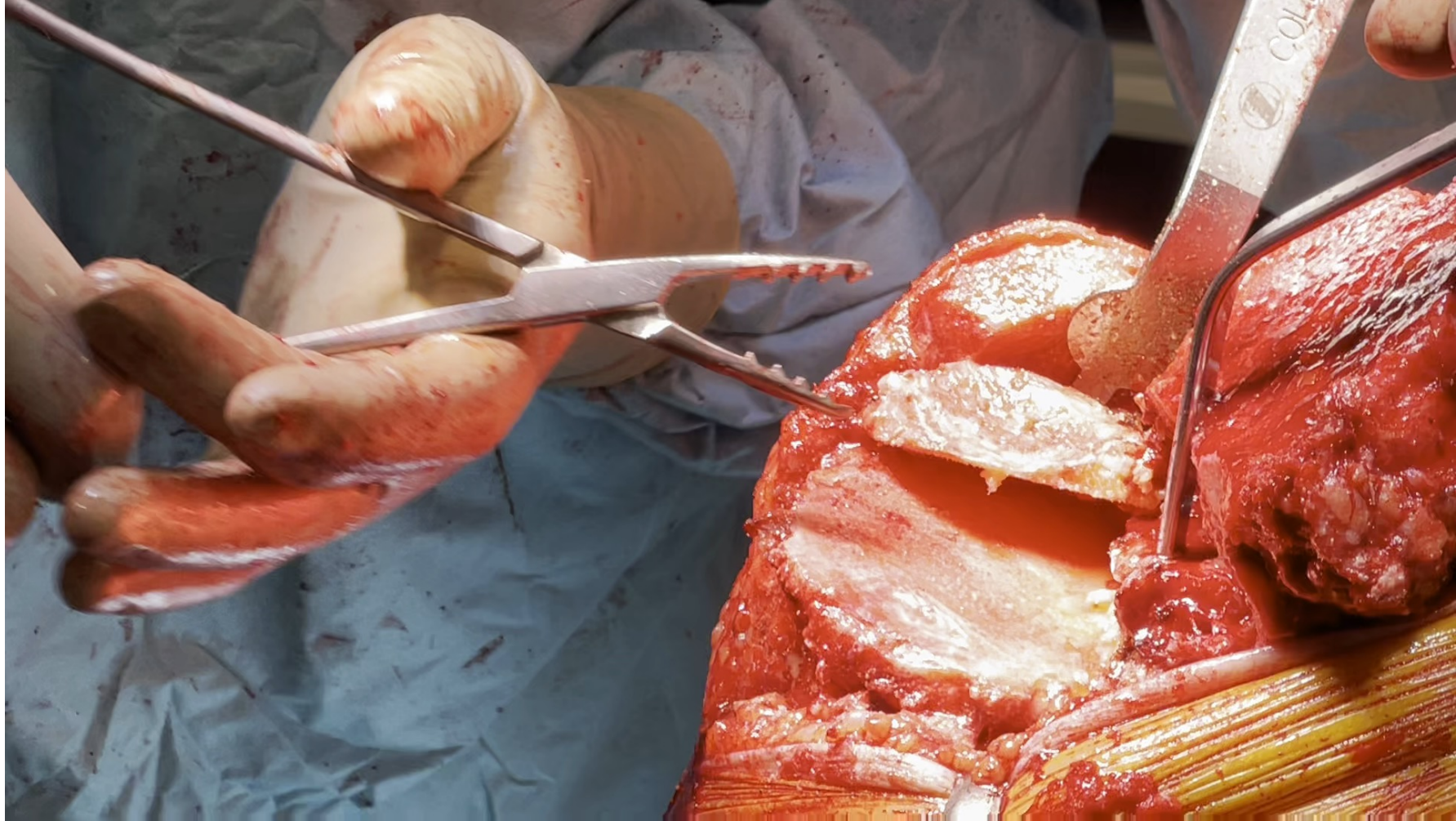

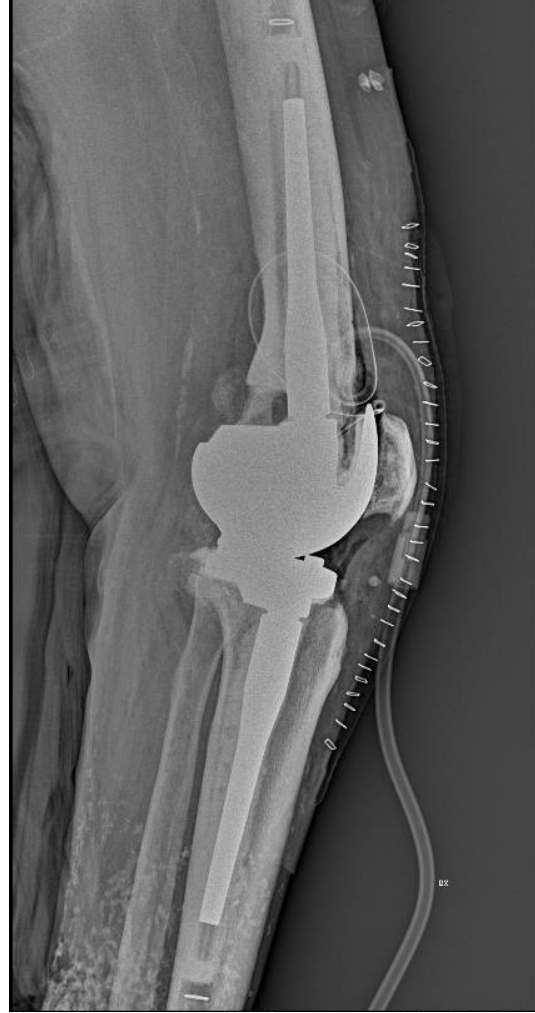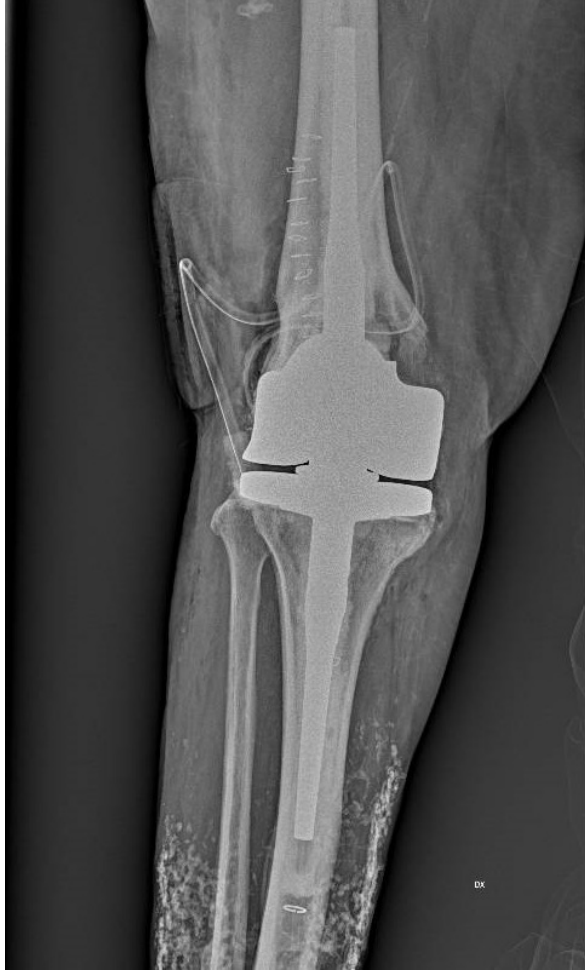Patella reshaping



Tibia proxiaml cut







Conclusions

- Sequential steps to be repeated / adapted to the anatomy and to the implant
- Degree of releases according to the severity of the deformity
- A la carte menu for difficult cases



